

Functional anatomy of Toraco- Abdominal Fascia and the morphogenesis structure of abdominal parietal fascia

FARRAJ MAIN

Department : Anatomy

University : Transilvania University Of Brasov

Address : Romania , Brasov city . str: branduselor , nr.41 , b.112, ap.34

ROMANIA

maanf@yahoo.com

Abstract: - A generally minimal, inexact, and sometimes ambiguous approach to fascial description arguably confounds clear recognition and understanding of this anatomical construct; and potentially constitutes a barrier to scholarly investigation of bodywork therapies as an Increasing international visibility of a growing raft of bodywork therapies raises questions about the theoretical underpinning of these clinical practices. Practitioner-written publications frequently hypothesize that the clinical application of bodywork techniques results in health-enhancing changes to the structure and function of fascia, however these assertions have yet to be established by research. Fascia provide a supportive and movable wrapping for nerves and blood vessels as they pass through and between muscles.

Key words: Fascia, endoabdominalFascia , morphogenesis structure of parietal fascia

1 Introduction

Fascia is the soft tissue component of the connective tissue system that permeates the human body. It forms a whole-body continuous three-dimensional matrix of structural support. Fascia interpenetrates and surrounds all organs, muscles, bones and nerve fibers, creating a unique environment for body systems functioning. The scope of our definition of and interest in fascia extends to all fibrous connective tissues, including aponeuroses, ligaments, tendons, retinaculae, joint capsules, organ and vessel tunics, the epineurium, the meninges, the periosteum, and all the endomysial and intermuscular fibers of the myofasciae.

2 Problem Formulation

Among the different kinds of tissues that are involved in musculoskeletal dynamics, fascia has received comparatively little scientific attention. Fascia, or dense fibrous connective tissues, nevertheless potentially plays a major and still poorly understood the role of Fascia , in general movement coordination, as well as in back pain and many other pathologies. One reason why fascia has not received adequate scientific attention in the past decades is that this tissue is so pervasive and interconnected that it easily frustrates the common ambition of researchers to divide it into a discrete

number of subunits which can be classified and separately described.

2 Problem Solution

A diverse assortment of definitions are applied to the term 'fascia' in both general and anatomical contexts. The researched sample of anatomical definitions varied considerably in length and content. Most contained information about fascial composition, structure , and function. Fewer references were made to fascial characteristics and location . While there were distinct similarities between the content of the sampled definitions and those published in anatomical textbooks, there were several noteworthy differences in meaning when compared to some of the bodywork textual descriptions. For that we studied 12 preserved fetus with ages between 5-8 months from Brasov obstetric and gynecology department , and 10 adult cadavres from the forensic and anatomy department Brasov were used for dissection of the abdominal region. And also were used for histological examination.

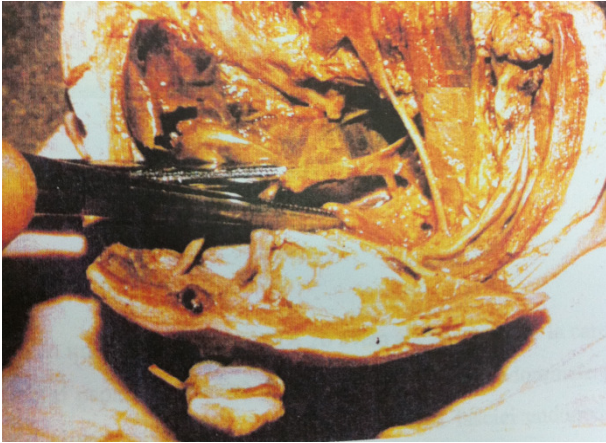

Fig 1. Endoabdominal Fascia high on the anterior abdominal wall.

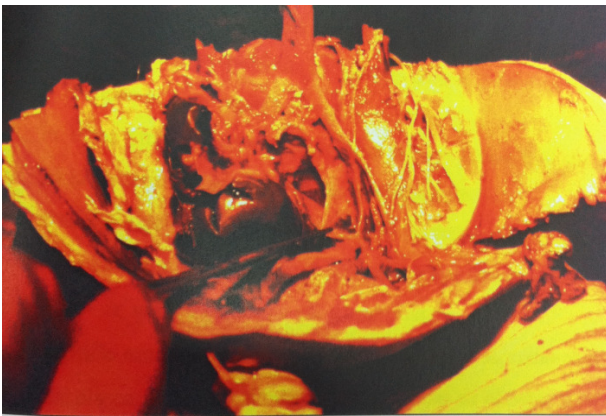

Fig 2. This part of endoabdominal fascia named pelviparietal fascia.

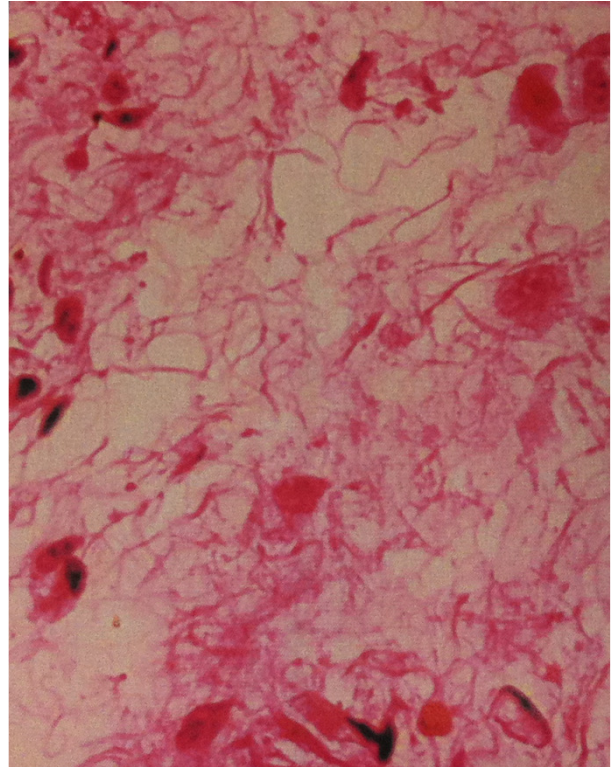


Fig 3. Histologic image from a fragment of endoabdominal fascia of a fetus was taken from the lumbar wall. (H.E., 600X)

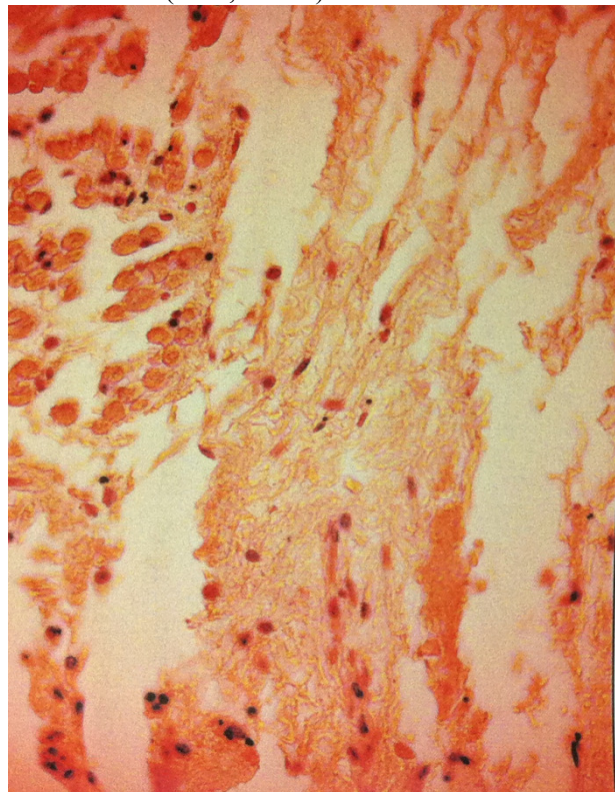


Fig 4. Endoabdominal fascia adult (size 100X)

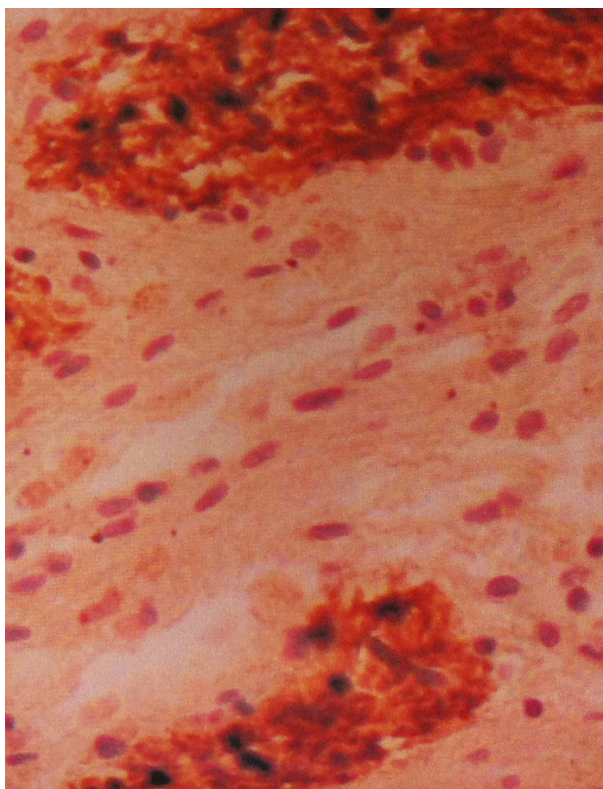


Fig 5 .Endoabdominal fascia of an adult (S-100-400X)

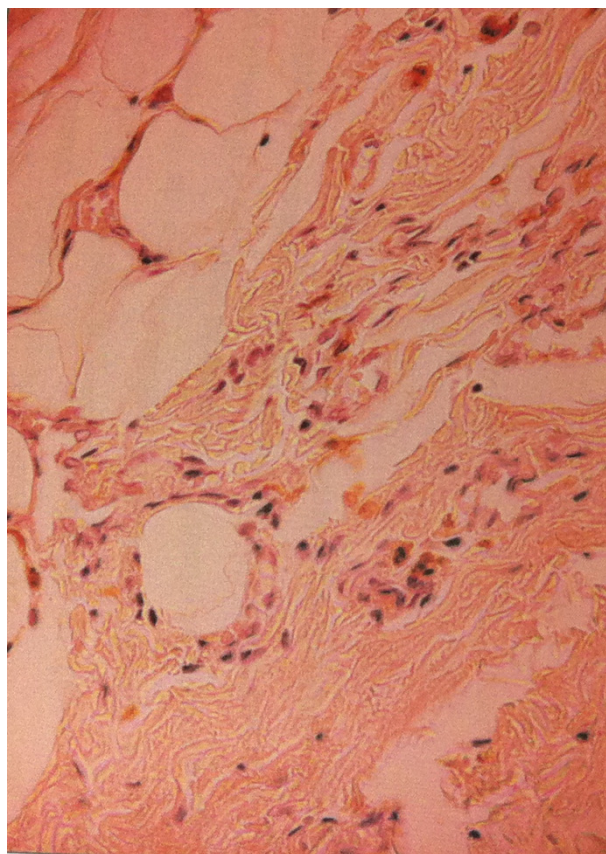


Fig 7. Endoabdominal fascia of an adult (S-100, 100 X)

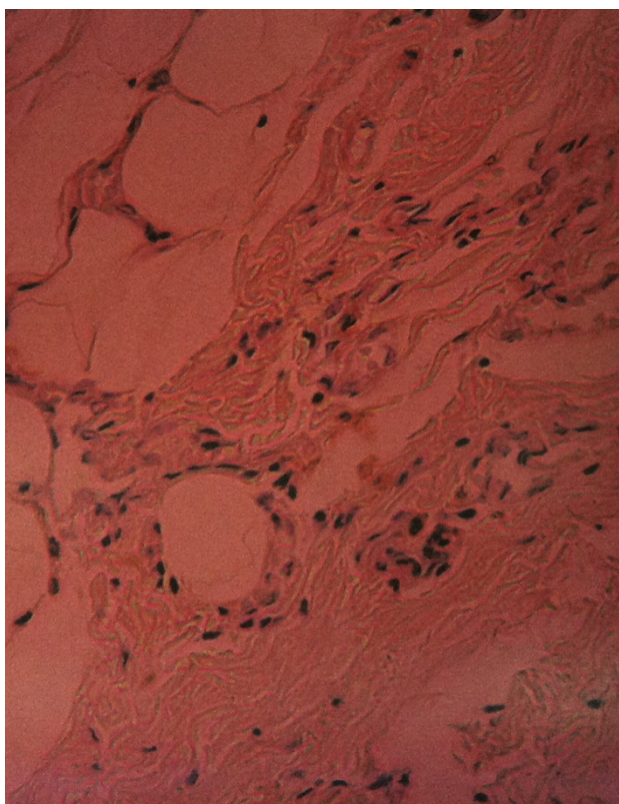


Fig 6 .Endoabdominal fascia of an adult (S-100, 100 X)

4 Conclusion

Definitions, including anatomical definitions, are culturally mediated constructs that powerfully influence downstream perception of meaning and merit. An historic paucity of interest in the comprehensive definition of fascia should not necessarily be construed to mean this soft tissue construct has no importance in the human body. In light of evolving explanations emerging from the bodywork literature, perhaps it is timely to revisit and review the semantic platform upon which these descriptions are based.

References:

1. ABU-HIJLEH M, ROSHIER A, AL-SHBOUL O, DHARAP A, HARRIS P : 2006 -The membranous layer of superficial fascia: evidence for its widespread distribution in the body ; Surgical and Radiological Anatomy, vol.28, nr.6:606-619
2. AN, H.S., SIMPSON, M.:1994- Surgery of the Cervical Spine; Taylor & Francis: 19

3. BAECHLE, T.R., EARLE, R.W.:2000- Essential of Strength Training and Conditioning;Health&Science: 58
4. BENNIGHOFF, GOERTTLER :1979 - Lehrbuch der Anatomie des Menschen vol.2, Eingeweide und Kreislauf - H. Ferner, J. Staubesand, ed.a 12-a Urban Schwarzenberg, Munchen-Wien - Baltimore : 87-90
5. BENNIGHOFF, GOERTTLER :1980 - Lehrbuch der Anatomie des Menschen vol.1, Allgemeine Anatomie, Cytologie und Bewegungsapparat - H. Ferner, J. Staubesand ed., a 13-a Urban Schwarzenberg, Munchen-Wien – Baltimore:81-83
6. BEYTH FJ, CULP LA: 1985- Glycosaminoglycan distribution in substratum adhesion sites of aging human skin fibroblasts, including papillary and reticular subpopulations. Mech Ageing Devel. 29:151
7. BOLE G.G.:1986 – Proteoglycans - in „Rheumatology and Immunology”;2nd Ed.-Cohen, Bennetts(Eds)-Grune& Stratton;49
8. BOUTLLIER, P.H. et.LEFORT:1970 - Etude anatomique du mezooesophage abdominal-deduction chirurgicales; J. Chir.Paris,nov. :35
9. BRAUS HERMANN - EIZE CURT:1934 - Anatomie des Menschen vol. 2, Eingeweide Berlin, Verlog von Julius Springer
10. BURGESON, R.E.: 1988 -New collagens, new concepts. Annu.Rev.Cell.Biol; 4:551-577.
- 11.CHUNG, KW:2004 –Gross Anatomy, 5th edition; Lippincott Williams & Wilkins 241-26014
- 12.CHUSIDJ. G.: 1982 - Manuel d'anatomie et de physiologieneurologiques; Ed.Masson :101
- 13.CLEMENTE, C.D.:2006- Clemente Anatomy Dissector, 13th ed.; lippincott Williams & Wilkins:170
- 14.COLBORN, G.L., SKANDALAKIS, J.E.:1993- Clinical Gross Anatomy: A Guide for Dissection; Informa Health Care: 443
- 15.CUNNINGHAM, D.J., ROBINSON, A.:1914- Cunningham Manual of Practical Anatomy, ; William Wood & Co: 147
- 16.DEMOSTHENES, B.:2004- Pleural Disease; Informa Health Care:26
- 17.DUGAN, DJ., SAMSON, PC :1975- Surgical significance of the endothoracic fascia; Am. J. Surg., 130:151-158
- 18.DYKES, M., AEERALLY, P. :2002 –Anatomy; Elsevier Health Sciences:103
- 19.FENEIS, H., DAUBER, W. :2000 –Pocket Atlas of Human Anatomy: Based on the International Nomenclature; 4th ed., Thieme
- 20.FORSTER CH.F, WEICHRAUCH:1976 - Diagnostik bei hiatus hernia und reflux krankheit- Dtsch.Med.Wischr.:52.